Overexpression of mitogen-activated protein kinase kinase 4 and nuclear factor-κB in laryngeal squamous cell carcinoma: A potential indicator for poor prognosis

CHUANG HUANG[1], KUN HUANG[2], CHI WANG[3], ZHEN-DONG JIANG[5], XING-XING LI[4], HONG-PENG WANG[1] and HONG-YAN CHEN[1]

Departments of [1]Otolaryngology and [2]Dermatology, The First Affiliated Hospital, Departments of [3]Pharmacology and [4]Biomedical Engineering, Chongqing Medical University, Chongqing 400016; [5]Department of Otolaryngology, Southwest Hospital, Third Military Medical University, Chongqing 400038, P.R. China

Received January 19, 2009; Accepted April 13, 2009

DOI: 10.3892/or_00000410

Abstract. This study aimed to investigate the expression and clinical significance of mitogen-activated protein kinase kinase 4 MKK4 and nuclear factor-κB (NF-κB) in patients with laryngeal squamous cell carcinoma (LSCC). We used immunohistochemistry (IHC) to examine the expression of MKK4 and NF-κB in 78 LSCCs and their adjacent normal tissues. To clarify the validity of MKK4 and NF-κB as determined by the IHC analysis, RT-PCR was performed on 21 tissues randomly selected from the 78 LSCCs. The positive expression rates of MKK4 and NF-κB in patients with LSCC were 67.9% (53/78) and 60.3% (47/78) respectively, which were significantly higher than those in the adjacent normal tissue (both P<0.01). The positive expression of MKK4 and NF-κB tended to be associated positively with lymph node metastasis (both P<0.01) as well as T stage (both P<0.01). The Spearman analysis indicated that the expression level of MKK4 was positively correlated with that of NF-κB significantly (rs=0.368, P<0.01). Overall survival curves estimated by Kaplan-Meier showed that tumor patients with low MKK4 and NF-κB expression in their tumor cells survive significantly longer than patients with high MKK4 and NF-κB levels (P=0.027, and P<0.01, respectively). In addition, multivariate Cox regression analysis showed that N stage, T stage and NF-κB expression are significant independent prognostic factors for overall survival (P<0.01, P=0.014, and P=0.027, respectively). These findings suggested that the expression of MKK4 and NF-κB may be considered as a useful prognostic marker of LSCC after surgical resection.

Correspondence to: Professor Hong-Yan Chen, Department of Otolaryngology, The First Affiliated Hospital, Chongqing Medical University, No.1 Youyi Road, Chongqing 400016, P.R. China
E-mail: cqchenhongyan@126.com

Key words: laryngeal squamous cell carcinoma, MKK4, NF-κB, immunohistochemistry, prognosis

Introduction

Mitogen-activated protein kinase kinase 4 (MKK4, also known as JNKK1, MAP2K4, and SEK1) is a dual-specificity kinase gene on chromosome 17p11 (1). MKK4 is a component of stress activated MAP kinase signaling modules. It directly phosphorylates and activates the c-Jun N-terminal kinase (JNK) and p38 families of MAP kinases in response to environmental stress, pro-inflammatory cytokines and developmental cues (1,2). In humans, it is reported that loss of function mutations in the MKK4 gene are found in approximately 5% of tumors from a variety of tissues, suggesting it may have a tumor suppression function (3). Furthermore, MKK4 has been identified as a suppressor of metastasis of prostate and ovarian cancers (4,5). However, the role of MKK4 in cancer development appears complicated as other studies support a pro-oncogenic role for MKK4 (6,7).

Nuclear factor-κB (NF-κB) is a signal transcription factor that has emerged as an important modulator of altered gene programs and malignant phenotype in development of cancer (8,9). Major carcinogens and oncogenic viruses induce NF-κB activation, and a variety of subsequent oncogenic events contribute to a progressive increase in constitutive NF-κB activation as an important common pathway in most forms of cancer. NF-κB target genes promote tumor cell proliferation, survival, migration, inflammation, and angiogenesis (10,11). Recent studies have shown that deletion of MKK4 gene enhances TNF-induced apoptosis through the down-regulation of NF-κB activation (12).

Laryngeal squamous cell carcinoma (LSCC) is very common in head and neck cancers. Local infiltration and cervical lymph node metastasis are often seen. Currently, there are few reports in literature on the expression of MKK4 and NF-κB in laryngeal cancer. In this study, we investigated

the expression of MKK4 and NF-κB in 78 patients with LSCC by immunohistochemistry. The aim of this study was to evaluate the expression of MKK4 and NF-κB as a biological marker in predicting the prognosis of laryngeal squamous cell carcinoma.

Materials and methods

Patients and tissue samples. Surgical specimens from 78 patients (39 patients with glottic lesions, 18 with supraglottic lesions, 5 with subglottic lesions, 16 with transglottic lesions) including cancer tissues and their adjacent normal tissues were obtained between January 2000 and December 2002 in the department of Otolaryngology, First Affiliated Hospital of Chongqing Medical University, China. They are pathologically confirmed LSCC. All resected surgical specimens were fixed with 10% buffered formalin and embedded in paraffin. In addition, the corresponding fresh tissue specimens used for RT-PCR analysis were immediately cut into small pieces and snap-frozen in liquid nitrogen. None of the patients had undergone radiotherapy or chemotherapy prior to operation. Among these patients, 70 were male and 8 were female, age ranged from 35 to 82 years, with a median age of 60.5 years. Histological grade included 41 patients of high grade, 26 of middle grade, and 11 of low grade. According to UICC stage (1997), there were 9 patients of T1, 31 of T2, 25 of T3, and 13 of T4. Neck stage included 51 patients of N0, 15 of N1, and 12 of N2. The clinical stage included 9 patients in stage I, 28 in stage II, 26 in stage III, and 15 in stage IV. Follow-up time for all the patients ranged from 6 to 92 months, with a median time of 66 months. The distribution of follow-up time for patients still alive at the time of analysis ranged from 62 to 92 months, with a median time of 72 months.

Our study of human materials was approved by the ethics committee of the First Affiliated Hospital of Chongqing Medical University. Informed consent was obtained from all the patients. All specimens were handled and made anonymous, according to the ethical and legal standards.

Immunohistochemical staining and assessment. Immunostaining was performed on 4-μm paraffin tissue sections mounted on poly-lysine-coated slides and dried at 37˚C overnight. After the slides were deparaffinized in xylene and rehydrated conventionally, the endogenous peroxidase was blocked with 3% hydrogen peroxide in methanol for 20 min. Each slide was incubated with normal goat serum for 20 min at room temperature. The sections were incubated with rabbit anti-MKK4 monoclonal antibody (1:80 dilution, Eptitomics, Inc., USA) and rabbit anti-NF-κB (p65) polyclonal antibody (1:100 dilution, Boster Biological Technology, Ltd., China), respectively overnight at 4˚C. After washing with PBS, sections were incubated for 30 min with a horseradish peroxidase labeled polymer anti-rabbit secondary antibody (Boster Biological Technology). Chromogen 3,3-diaminobenzidine (Boster Biological Technology) was used for 15 min to visualize immunolabeling, resulting in a brown precipitate. After washing, the sections were counterstained with hematoxylin. Positive and negative immunohistochemistry controls were routinely performed.

To evaluate the expression of MKK4 and NF-κB, three independent observers without knowledge of any clinicopathologic data examined the immunostaining. The numbers of MKK4 positive cells that showed immunoreactivity on the cell cytoplasm and NF-κB on the cytoplasm and/or nucleus in ten representative microscopic fields were counted and the percentages of positive cells were calculated. The criteria used for assessment were previously reported (13) as follows: -, negative; +,1-25% positive cells; ++, 25-75% positive cells; +++,75-100% positive cells.

Detection of MKK4 and NF-κB expression by RT-PCR. To evaluate MKK4 and NF-κB expression at the RNA level, 21 randomly selected LSCC tissues (all included in the cohort for immunohistochemisry) previously preserved were retrieved. Total RNA was extracted using TRIzol solution (Invitrogen) according to the manufacturer's protocol. And RNase-free DNase I was used to remove DNA contamination. Total RNA concentration and quantity were assessed by absorbency at 260 nm using a DNA/Protein Analyzer (DU 530, Beckman, USA). Reverse transcription (RT) was performed in a 20 μl reaction system with 2 μg total RNA treated by AMV reverse transcriptase to synthesis first strand cDNA (Takara Biotechnology, China) according to the manufacturer's recommendation, followed by cDNA amplification with ß-actin as an internal control. The sequences of the sense and antisense primers were as follows: MKK4 (180 bp), 5'-GCAACTGTGAAAGCACTAAACC-3' (sense) and 5'-CATGTATGGCCTACAGCCAG-3' (antisense); NF-κB (400 bp), 5'-TCAATGGCTACACAGGACCA-3' (sense) and 5'-ATCTTGAGCTCGGCAGTGTT-3' (antisense); ß-actin (285 bp), 5'-AGCGAGCATCCCCCAAAGTT-3' (sense) and 5'-GGGCACGAAGGCTCATCATT-3' (antisense). cDNA templates were amplified using Taq polymerase (Takara Biotechnology) per 10 μl of PCR reaction. Initial melting (94˚C for 2 min) was followed by 40 cycles of 94˚C for 30 sec, 55˚C or 60˚C for 30 sec (MKK4 and NF-κB, respectively) and 72˚C for 1 min; 10 min at 72˚C was used for final extension following cycling. The PCR products were observed by electrophoresis on 1.5% agarose gel and visualized after staining with ethidium bromide. To quantify the densities of the bands, the gray values were measured using the Bio-Rad imaging system.

Statistical analysis. Statistical Package for the Social Sciences (SPSS Inc, USA) 13.0 was used for statistical analysis. Mann-Whitney U test and Kruskall-Wallis test were used for comparing the groups. Kaplan-Meier method for the question of survival, and Cox regression analysis for the multivariate analysis. The Spearman correlation was calculated between the expression levels of MKK4 and NF-κB in laryngeal squamous cell carcinoma tissues. The difference was considered to be significant when the P-value was <0.05.

Results

RT-PCR analysis. To confirm whether MKK4 and NF-κB expression evaluated by immunohistochemistry was largely paralleled at the mRNA level, cDNAs from 21 LSCCs

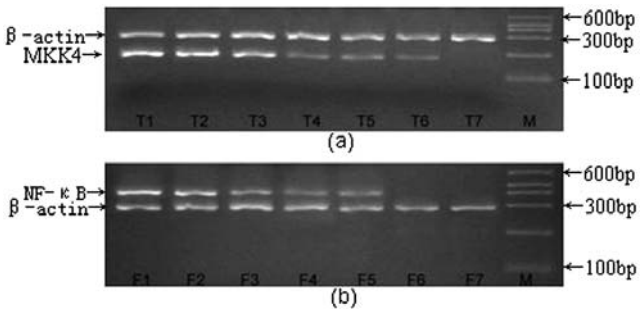

Figure 1. Detection of MKK4 and NF-κB expression by RT-PCR in LSCC. T1-T3, LSCC with moderate-high expression of MKK4 detected by IHC; T4-T7, LSCC with immunohistochemically negative or low expression of MKK4 (a). F1-F3, LSCC with moderate-high expression of NF-κB detected by IHC; F4-F7, LSCC with immunohistochemically negative or low expression of NF-κB (b). M, DNA size marker. ß-actin was amplified simultaneously and served as internal control.

were amplified using MKK4 and NF-κB specific primers. As shown in Fig. 1, T1-T3 and F1-F3 had immunohistochemically moderate-high expression, while T4-T7 and F4-F7 had negative or low expression for MKK4 and NF-κB respectively, indicating that up-regulation of MKK4 and NF-κB in tumor tissues by immunohistochemistry was correlated with mRNA levels (rs=0.875, P<0.01, and rs=0.752, P<0.01, respectively). We, therefore, further examined expression of MKK4 and NF-κB in LSCC by immunohistochemistry alone in this study.

Expression of MKK4 and NF-κB in LSCC and adjacent normal tissues. The positive expression rate of MKK4 and NF-κB protein in 78 patients with LSCC were 67.9% (53/78) and 60.3% (47/78), respectively. However, the expression in adjacent normal tissues was only 52.6% (41/78) and 33.3% (26/78), respectively (Fig. 2). The differences in the positive expression rates of two proteins between tumorous and adjacent normal tissues have statistical significance (both P<0.01, Table I).

Relationship between clinicopathological features and expression of MKK4 and NF-κB. Table II shows the relationship between clinicopathological features of LSCC and the expression of MKK4 and NF-κB. The positive expression of MKK4 and NF-κB was not related with the age, gender, primary site, differentiation or clinical stage of LSCC patients.

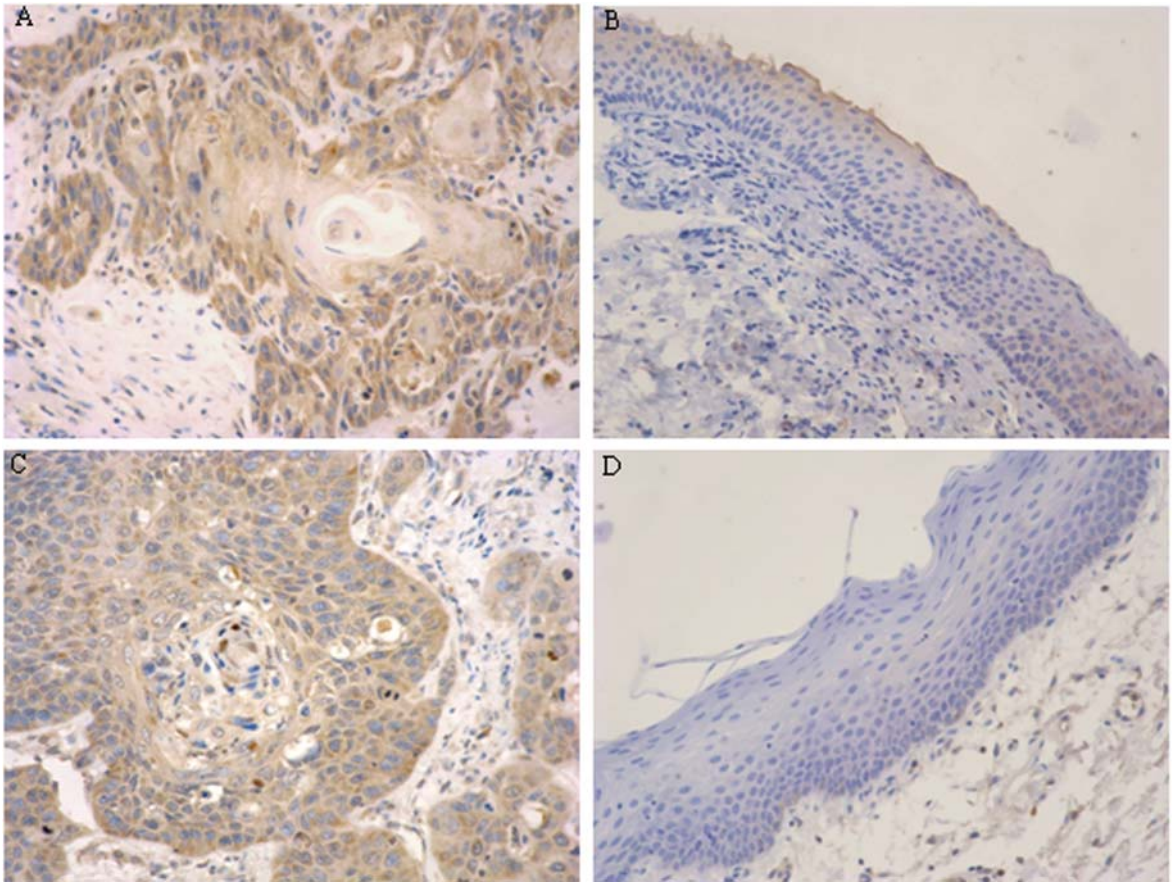

Figure 2. Immunohistochemical analysis showed MKK4 and NF-κB overexpression in human LSCC as compared with adjacent normal tissues. (A) Positive staining of MKK4 in LSCC (original magnification x400). (B) Negative or weak staining of MKK4 in adjacent normal tissues (original magnification x400). (C) Positive staining of NF-κB in LSCC (original magnification x400). (D) Negative or weak staining of NF-κB in adjacent normal tissues (original magnification x400).

Table I. Expression of MKK4 and NF-κB in LSCC and adjacent normal tissues.

		MKK4					NF-κB				
Type	n	-	+	++	+++	P-value	-	+	++	+++	P-value
Cancer tissues	78	25	12	27	14	<0.01	31	10	25	12	<0.01
Normal tissues	78	37	15	22	4		52	16	7	3	

Table II. The relationship between the expression of MKK4 and NF-κB and clinicopathological features of LSCC.

		MKK4					NF-κB				
Classifcation	n	-	+	++	+++	P-value	-	+	++	+++	P-value
Age											
≥60	38	11	7	11	9	0.484	14	3	13	8	0.227
<60	40	14	5	16	5		17	7	12	4	
Gender											
Male	70	23	12	22	13	0.530	29	9	21	11	0.476
Female	8	2	0	5	1		2	1	4	1	
Primary sites											
Glottic	39	12	4	14	9	0.178	15	4	14	6	0.684
Supraglottic	18	8	4	6	0		8	3	6	1	
Subglottic	5	1	1	3	0		2	1	2	0	
Transglottic	16	4	3	4	5		6	2	3	5	
Differentiation											
High	41	15	5	13	8	0.942	13	5	16	7	0.161
Middle	26	7	5	10	4		14	3	7	2	
Low	11	3	2	4	2		4	2	2	3	
T stage											
T1 + T2	40	18	9	8	5	<0.01	21	8	8	3	<0.01
T3 + T4	38	7	3	19	9		10	2	17	9	
N stage											
N-	51	21	9	15	6	<0.01	24	8	15	4	<0.01
N+	27	4	3	12	8		7	2	10	8	
Clinical stage											
I + II	37	14	7	11	5	0.142	18	4	10	5	0.187
III + IV	41	11	5	16	9		13	6	15	7	

The positive expression of these two markers tended to be associated positively with lymph node metastasis (both P<0.01) as well as T stage (both P<0.01).

The Spearman analysis indicated that the expression level of MKK4 was positively correlated with that of NF-κB significantly (rs=0.368, P<0.01).

MKK4 and NF-κB status and prognosis of LSCC. Overall survival curves estimated by Kaplan-Meier showed that tumor patients with low MKK4 and NF-κB expression in their tumor cells survive significantly longer than patients with high MKK4 and NF-κB levels (P=0.027, and P<0.01, respectively, Figs. 3 and 4). The univariate survival analysis disclosed N stage, T stage, clinical stage, MKK4 expression and NF-κB expression as significant prognostic factors and the final Cox model including all such variables (Table III). Multivariate Cox regression analysis showed that N stage, T stage and NF-κB expression were significant independent prognostic factors for overall survival (P<0.01, P=0.014, and P=0.027, respectively, Table IV).

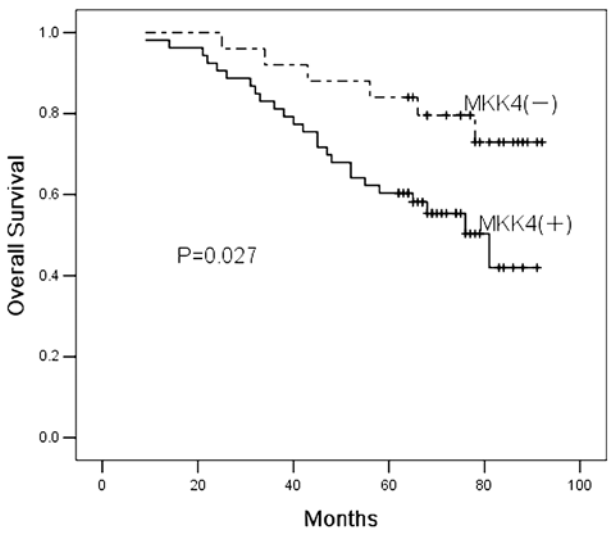

Figure 3. The overall survival Kaplan-Meier curves in patients with positive and negative expression of MKK4.

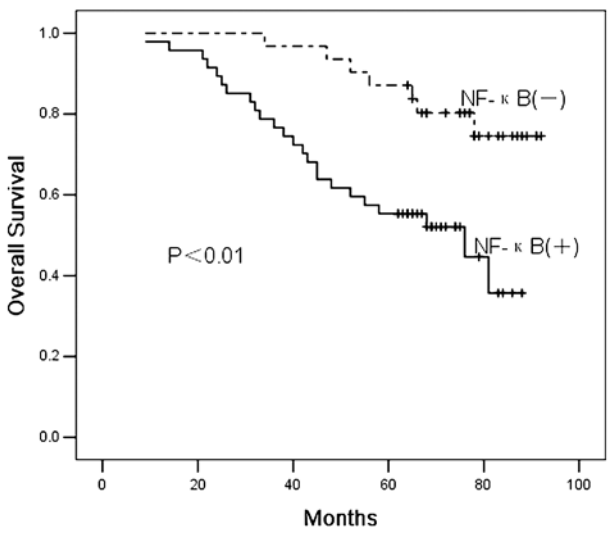

Figure 4. The overall survival Kaplan-Meier curves in patients with positive and negative expression of NF-κB.

Table IV. Multivariate Cox regression analysis for overall survival in 78 patients with LSCC.

					95.0% CI for Exp (B)	
Variable	Wald	df	p-value	Exp (B)	Lower	Upper
NF-κB	4.922	1	0.027	2.812	1.128	7.007
T stage	6.017	1	0.014	3.503	1.287	9.540
N stage	10.366	1	<0.01	5.108	1.893	13.786

Discussion

Over the past decade, a number of studies have supported a role for MKK4 in regulating steps in the development of cancers. Many studies proposed that MKK4 is a tumor suppressor and a suppressor of metastasis. For instance, ample evidence of inactivating somatic mutations of MKK4 in cancers defines this gene as a candidate tumor-suppressor gene (3,14,15). The impaired expression of MKK4 in prostate and ovarian tumors appears to promote their metastases (4,5), while reduced MKK4 mRNA levels have been reported in breast cancer to brain metastases (16). However, there are conflicting data on the role of MKK4 in carcinogenesis. Wang *et al*, recently reported evidence for MKK4 having pro-oncogenic activity in an experimental setting (6). Additional evidence for a role of MKK4 in cell proliferation comes from the demonstration that the expression of a dominant-negative mutant of MKK4 in H1299 non-small-cell lung cancer (NSCLC) cells cooperated with the inhibition of the phosphatidylinositol 3-kinase signaling pathway to block cell proliferation and reduce the size of H1299 NSCLC xenograft tumors (7), whereas the overexpression of a constitutively active mutant of MKK4 in human bronchial epithelial cell lines increased their proliferation and invasive properties (17).

To date, there are no studies evaluating the relationship of the expression of MKK4 in LSCC tissue to clinicopathological

Table III. Univariate Cox regression analysis for overall survival in 78 patients with LSCC.

					95.0% CI for Exp (B)	
Variable	Wald	df	p-value	Exp (B)	Lower	Upper
Age	0.202	1	0.653	1.177	0.578	2.397
Gender	0.007	1	0.935	0.952	0.289	3.139
MKK4	4.552	1	0.033	2.662	1.083	6.543
NF-κB	7.950	1	<0.01	3.406	1.453	7.982
T stage	16.694	1	<0.01	5.776	2.491	13.397
N stage	27.732	1	<0.01	10.202	4.298	24.217
Clinical stage	3.922	1	0.048	2.086	1.008	4.320
Differentiation	0.691	1	0.406	1.223	0.761	1.967
Primary sites	0.367	1	0.545	1.099	0.810	1.492

features and prognosis. Our results indicated that MKK4 was expressed in both LSCC and adjacent normal tissues, but their expression levels varied between the two tissue types. In LSCC, the expression level of MKK4 was significantly higher compared to the normal tissues. Our results also showed that a high expression of MKK4 on LSCC tumor cells correlated with shortened patient survival, higher T stages, and higher stages of neck lymph nodes. These observations coincided with an earlier study which demonstrated that a higher MKK4 expression was shown to be an adverse prognostic marker inversely associated with the overall and relapse-free survivals in gastric cancer (13). Furthermore, our results showed that MKK4 protein expression in LSCC tissue is not a significant independent prognostic factor.

The conflicting biological responses of MKK4 in human malignancy may in fact reflect the complexity of MAPK signal transduction. The biological activity of MKK4 in tumors has not been systematically examined. Moreover, cell type- or model-specific differences have produced previously paradoxical findings. Our statistical analysis of MKK4 protein expression and clinicopathological features indicated that MKK4 kinase could serve as a pro-oncogenic molecule in LSCC.

There is now considerable evidence that sustained or constitutive activation of NF-κB is prevalent in cell lines and tumor tissue specimens and contributes to malignant progression in most of the major forms of human cancer (18-22). Our results showed obvious overexpression of NF-κB in human LSCC tissues as compared with the adjacent normal tissues. This finding was in line with the prior studies which showed that NF-κB was overexpressed in laryngeal cancer, compared to precancerous lesions (23). Similar to MKK4, we also observed that NF-κB overexpression in LSCC tissue was associated with a significantly shorter survival, an increased risk of neck lymph nodes metastasis, and a higher T stage. Moreover, in multivariate analysis, NF-κB was found to be an independent and powerful prognostic factor in LSCC.

We have noted that a significant positive association between MKK4 and NF-κB immunoreactivity. Based upon this finding, we concluded that the presence of MKK4 may indirectly activate NF-κB and the two markers contribute to carcinogenesis and tumor progression in LSCC. Our conclusion are in compatible with the findings of Xia *et al* (24). They showed that MKK4 promotes cell survival by activating phosphatidylinositol 3-kinase through an NF-κB/PTEN-dependent pathway and demonstrated that MKK4 regulated NF-κB through an IKK-independent pathway. Our findings are further supported by the results of Sethi *et al* (12). They found that targeted deletion of MKK4 gene potentiates TNF-induced apoptosis through the down-regulation of NF-κB activation. In addition, Lee *et al* (25) reported that activated MEKK1 phosphorylates MKK4, which in turn phosphorylates IKK, supporting the idea that a MEKK1-MKK4-IKK complex participates in the activation of NF-κB by TNF-α in rheumatoid arthritis fibroblast-like synovial cells. However, how the deletion of MKK4 leads to suppression of NF-κB activation is not clear.

In summary, this study suggested that MKK4 and NF-κB could be used as good tools to assess the prognosis in LSCC as their expression directly correlates with N stage, T stage and overall survival. Moreover, our findings also provide evidence that NF-κB could serve as an independent prognostic factor in LSCC. Thus, MKK4 and NF-κB expression may be considered as a useful prognostic markers of LSCC after surgical resection.

References

1. Dérijard B, Raingeaud J, Barrett T, Wu IH, Han J, Ulevitch RJ and Davis RJ: Independent human MAP kinase signal transduction pathways defined by MEK and MKK isoforms. Science 267: 682-685, 1995.
2. Lin A, Minden A, Martinetto H, *et al*: Identification of a dual specificity kinase that activates the Jun kinases and p38-Mpk2. Science 268: 286-290, 1995.
3. Teng DH, Perry WL III, Hogan JK, *et al*: Human mitogen-activated protein kinase kinase 4 as a candidate tumor suppressor. Cancer Res 57: 4177-4182, 1997.
4. Yoshida BA, Dubauskas Z, Chekmareva MA, Christiano TR, Stadler WM and Rinker-Schaeffer CW: Mitogen-activated protein kinase kinase 4/stress-activated protein/Erk kinase 1 (MKK4/SEK1), a prostate cancer metastasis suppressor gene encoded by human chromosome 17. Cancer Res 59: 5483-5487, 1999.
5. Yamada SD, Hickson JA, Hrobowski Y, *et al*: Mitogen-activated protein kinase kinase 4 (MKK4) acts as a metastasis suppressor gene in human ovarian carcinoma. Cancer Res 62: 6717-6723, 2002.
6. Wang L, Pan Y and Dai JL: Evidence of MKK4 pro-oncogenic activity in breast and pancreatic tumors. Oncogene 23: 5978-5985, 2004.
7. Lee HY, Oh SH, Suh YA, Baek JH, Papadimitrakopoulou V, Huang S and Hong WK: Response of non-small cell lung cancer cells to the inhibitors of phosphatidylinositol 3-kinase/Akt- and MAPK kinase 4/c-Jun NH2-terminal kinase pathways: an effective therapeutic strategy for lung cancer. Clin Cancer Res 11: 6065-6074, 2005.
8. Hayden MS and Ghosh S: Signaling to NF-kappaB. Genes Dev 18: 2195-224, 2004.
9. Luo JL, Kamata H and Karin M: IKK/NF-kappaB signaling: balancing life and death-a new approach to cancer therapy. J Clin Invest 115: 2625-2632, 2005.
10. Karin M and Ben-Neriah Y: Phosphorylation meets ubiquitination: the control of NF-[kappa]B activity. Annu Rev Immunol 18: 621-663, 2000.
11. Baldwin AS: Control of oncogenesis and cancer therapy resistance by the transcription factor NF-kappaB. J Clin Invest 107: 241-246, 2001.
12. Sethi G, Ahn KS, Xia D, Kurie JM and Aggarwal BB: Targeted deletion of MKK4 gene potentiates TNF-induced apoptosis through the down-regulation of NF-{kappa}B activation and NF-{kappa}B-regulated antiapoptotic gene products. J Immunol 179: 1926-1933, 2007.
13. Wu CW, Li AF, Chi CW, Huang CL, Shen KH, Liu WY and Lin W: Human gastric cancer kinase profile and prognostic significance of MKK4 kinase. Am J Pathol 156: 2007-2015, 2000.
14. Su GH, Hilgers W, Shekher MC, Tang DJ, Yeo CJ, Hruban RH and Kern SE: Alterations in pancreatic, biliary, and breast carcinomas support MKK4 as a genetically targeted tumor suppressor gene. Cancer Res 58: 2339-2342, 1998.
15. Su GH, Song JJ, Repasky EA, Schutte M and Kern SE: Mutation rate of MAP2K4/MKK4 in breast carcinoma. Hum Mutat 19: 81-84, 2002.
16. Stark AM, Tongers K, Maass N, Mehdorn HM and Held-Feindt J: Reduced metastasis-suppressor gene mRNA-expression in breast cancer brain metastases. J Cancer Res Clin Oncol 131: 191-198, 2005.
17. Khatlani TS, Wislez M, Sun M, *et al*: c-Jun N-terminal kinase is activated in non-small-cell lung cancer and promotes neoplastic transformation in human bronchial epithelial cells. Oncogene 26: 2658-2666, 2007.
18. Sovak MA, Bellas RE, Kim DW, Zanieski GJ, Rogers AE, Traish AM and Sonenshein GE: Aberrant nuclear factor-kappaB/Rel expression and the pathogenesis of breast cancer. J Clin Invest 100: 2952-2960, 1997.

19. Okano H, Shiraki K, Inoue H, *et al*: Fas stimulation activates NF-kappaB in SK-Hep1 hepatocellular carcinoma cells. Oncol Rep 10: 1145-1148, 2003.
20. Kojima M, Morisaki T, Sasaki N, Nakano K, Mibu R, Tanaka M and Katano M: Increased nuclear factor-kB activation in human colorectal carcinoma and its correlation with tumor progression. Anticancer Res 24: 675-681, 2004.
21. Ondrey FG, Dong G, Sunwoo J, *et al*: Constitutive activation of transcription factors NF-(kappa)B, AP-1, and NF-IL6 in human head and neck squamous cell carcinoma cell lines that express pro-inflammatory and pro-angiogenic cytokines. Mol Carcinog 26: 119-129, 1999.
22. Zucchini C, Rocchi A, Manara MC, *et al*: Apoptotic genes as potential markers of metastatic phenotype in human osteosarcoma cell lines. Int J Oncol 32: 17-31, 2008.
23. Kourelis K, Sotiropoulou-Bonikou G, Vandoros G, Repanti M, Varakis I and Goumas P: Coordinated upregulation of COX-2 and NF-kappaB is a steady feature of laryngeal carcinogenesis. ORL J Otorhinolaryngol Relat Spec 69: 181-189, 2007.
24. Xia D, Srinivas H, Ahn YH, *et al*: Mitogen-activated protein kinase kinase-4 promotes cell survival by decreasing PTEN expression through an NF kappa B-dependent pathway. J Biol Chem 282: 3507-3519, 2007.
25. Lee CK, Lee EY, Kim YG, Mun SH, Moon HB and Yoo B: Alpha-lipoic acid inhibits TNF-alpha induced NF-kappaB activation through blocking of MEKK1-MKK4-IKK signaling cascades. Int Immunopharmacol 8: 362-370, 2008.