PathologyOutlines.com

WHAT'S NEW IN PATHOLOGY?

Issue 9 || September 2018

THE LATEST NEWS IN HEMEPATH

By Genevieve Crane M.D., Ph.D.

What's New in Hematopathology part 1 focuses on changes to lymphoid malignancies important for your practice plus emerging areas of interest. It includes the revised WHO Classification of Tumours of Haematopoietic and Lymphoid Tissues, 4th Edition, 2017 as well as molecular data for prognosis and treatment. Part 2 will discuss myeloid malignancies.

Large B Cell Lymphoma

- **High grade B cell lymphoma (HGBL) with rearrangements of *MYC* and *BCL2* or *BCL6***: new category for "double hit" or "triple hit" lymphomas; excludes cases that fulfill criteria for follicular or lymphoblastic lymphoma.
- **HGBL, not otherwise specified (NOS)**: blastoid or intermediate between diffuse large B cell lymphoma (DLBCL) and Burkitt morphology but lack *MYC* and *BCL2* or *BCL6* rearrangement.
- **Double expressor phenotype**: expression of MYC (> 40%) with BCL2 (> 50%), often without MYC / BCL2 translocation; may be more aggressive than DLBCL, NOS but generally less so than HGBL.
- **Burkitt-like lymphoma with 11q aberration**: lacks characteristic *MYC* rearrangements; has chromosome 11q alterations and more cytologic pleomorphism than Burkitt; frequently nodal.
- **DLBCL, NOS**: cell of origin subclassification is required: either germinal center B cell-like (GCB) or activated B cell-like (ABC) / non GCB; associated with different chromosomal alterations, signaling pathways and clinical outcome (ABC typically worse), immunohistochemical algorithms acceptable (e.g. Hans algorithm).
- **Genetic landscape of DLBCL**: large scale sequencing suggests revision to DLBCL subsets, risk stratification and potential treatment strategies (Cell 2017;171:481, Nat Med 2018;24:679, N Engl J Med 2018;378:1396).
- **EBV$^+$ DLBCL, NOS**: "elderly" term now dropped but typically affects immunocompetent patients > 50 years old; generally worse prognosis than EBV$^-$ cases; excludes specific EBV$^+$ subtypes (e.g. lymphomatoid granulomatosis).

Supported by an unrestricted grant from the United States and Canadian Academy of Pathology

Mantle Cell Lymphoma (MCL)

- Classically aggressive, now two clinically indolent variants recognized:
  - **Leukemic nonnodal MCL**: has *IGHV* mutated SOX11$^-$ B cells; usually involves blood, bone marrow, often spleen; indolent but secondary abnormalities (e.g. *TP53* mutation) may result in aggressive disease.
  - **In situ mantle cell neoplasia**: replaces "in situ MCL"; often incidental; cyclin D1$^+$ cells in the inner mantle zones of follicles but lacks other features to suggest MCL.

Revised Follicular Lymphoma (FL) Variants

- **In situ follicular neoplasia**: replaces in situ FL; has low rate of progression, often associated with prior or synchronous overt lymphomas; distinguish from partial involvement by FL.
- **Duodenal type FL (Fig. 1)**: now recognized as distinct from other GI tract FL; features overlap with in situ follicular neoplasia and MALT lymphoma; has excellent outcome, often with a watch and wait strategy.

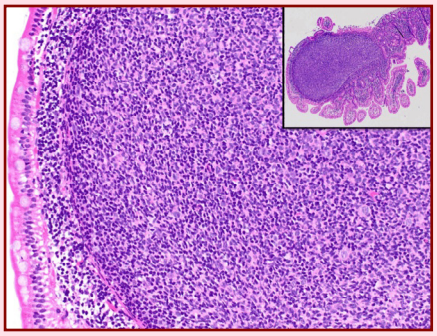

***Fig. 1**: Duodenal type follicular lymphoma. Incidental finding, excellent prognosis.*

- **Pediatric type FL**: now a definite entity affecting children and young adults; is a localized nodal disease with low malignant potential; has expansile, highly proliferative follicles but no *BCL2*, *BLC6* or *MYC* rearrangements.
- **Large B cell lymphoma with *IRF4* rearrangement**: new provisional entity of children and young adults affecting Waldeyer ring or cervical lymph nodes; typically low stage; has strong IRF4 / MUM1, BCL6 expression and high proliferation rate.
- **CD10$^-$, IRF4 / MUM1$^+$ FL**: often associated with high grade morphology; older individuals.

Other Low Grade B Cell

- **Hairy cell leukemia**: *BRAF* V600E mutations in almost all cases.
- **Hairy cell leukemia variant**: *MAP2K1* mutations, preferential *IGHV4* - 34 gene family usage.
- **Splenic diffuse red pulp small B cell lymphoma (Fig. 2)**: provisional entity; uncommon; diffuse involvement of splenic red pulp and bone marrow sinusoids by small, monomorphic lymphocytes and circulating villous lymphocytes.

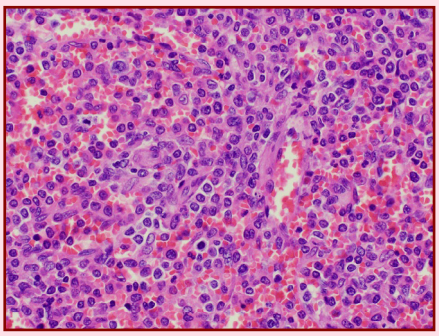

Fig. 2: Splenic diffuse red pulp small B cell lymphoma. New provisional entity.

• **Lymphoplasmacytic lymphoma**: *MYD88* L265P in 90% of cases but not specific (also in DLBCL ABC type); concurrent *CXCR4* mutations (30%) associated with higher bone marrow involvement and reduced response to ibrutinib (Leukemia 2015;29:169).
• **Monoclonal B cell lymphocytosis**: has up to 5×10^9/L circulating monoclonal B cells, often with a CLL phenotype, but no other lymphomatous features; "low count" (up to 0.5×10^9/L) only rarely progresses.

Immunosuppression Related

• **DLBCL associated with chronic inflammation**: long standing chronic inflammation, EBV$^+$, includes **pyothorax associated lymphoma** and **fibrin associated DLBCL (Fig. 3)** (usually incidental finding).

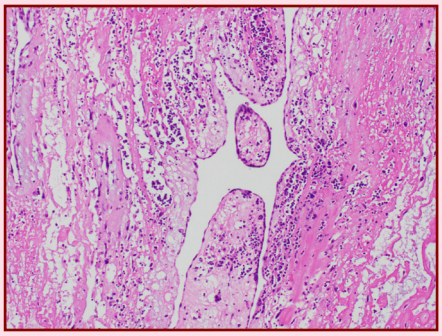

Fig. 3: Cardiac myxoma with incidental finding of fibrin associated DLBCL.

• **EBV$^+$ mucocutaneous ulcer**: provisional entity with Hodgkin-like features, age related or iatrogenic immunosuppression, typically indolent with spontaneous regression.
• **EBV$^+$ marginal zone lymphoma**: now considered a posttransplant lymphoproliferative disorder (Am J Surg Pathol 2018 Jun 27 [Epub ahead of print]).

T Cell Lymphomas (TCL)

• **Peripheral T cell lymphoma (PTCL), NOS**: very heterogeneous group actively studied to better subclassify.
• **Nodal lymphomas of T follicular helper (TFH) cell origin**:
  • **Angioimmunoblastic T cell lymphoma (AITL)** remains a distinct entity with characteristic morphologic findings and systemic disease.
  • **Follicular TCL**: morphology resembles follicular lymphoma or progressive transformation of germinal centers; lacks the vascular proliferation and expanded dendritic meshworks of AITL.
  • **Nodal PTCL with TFH phenotype**: no longer part of PTCL, NOS; shares recurrent genetic alterations with AITL.
  • **Node based EBV$^+$ PTCL**: associated with immunodeficiency; most neoplastic cells are EBV$^+$; no angioinvasion or necrosis as seen in extranodal NK / TCL.
• **ALK$^-$ Anaplastic Large Cell Lymphoma (ALCL)**: no longer provisional, improved criteria to distinguish from CD30$^+$ PTCL, NOS; rearrangements at *DUSP22* and *IRF4* locus (6p25) provide superior prognosis; *TP63* rearrangements (small subset) are very aggressive.
• **Breast implant associated ALCL**: usually confined to seroma / fibrous capsule enabling conservative management.
• **Enteropathy associated TCL**: formerly EATL type I; closely linked to celiac disease; cells are typically polymorphic.
• **Monomorphic epitheliotropic intestinal TCL**: formerly EATL type II; not associated with celiac disease; cells are monomorphic, usually CD8$^+$, CD56$^+$ and CD5$^-$ with gains in chromosome 8q24 (*MYC*).
• **Primary cutaneous CD4$^+$ small / medium T cell lymphoproliferative disease**: indolent, localized, TFH phenotype which lacks the genetic profile of nodal TFH lymphomas.
• **New provisional entities** are **indolent T cell lymphoproliferative disorder of the GI tract** and **primary cutaneous acral CD8$^+$ TCL** (first identified on ear); both are clonal, usually CD8$^+$ and indolent.
• **Systemic EBV$^+$ TCL of childhood**: no longer "lymphoproliferative disorder" due to fulminant clinical course usually associated with a hemophagocytic syndrome.

Lymphoblastic Lymphoma

• **Early T precursor acute lymphoblastic leukemia (ALL)**: retains some myeloid and stem cell features by immunophenotype and gene expression profile; CD7$^+$, CD1a$^-$, CD8$^-$; positive for at least one myeloid / stem cell marker.
• **B lymphoblastic leukemia / lymphoma *BCR-ABL1*-like**: new provisional category with similar gene expression as ALL with *BCR-ABL*; often has translocations of other tyrosine kinases such as *ETV6-JAK2* or *BCR-JAK2* or involving *CRLF2*; has poor prognosis.

Meet the Author

Genevieve Crane, MD, PhD is an Assistant Professor at Weill Cornell Medicine/ NY Presbyterian Hospital in the Division of Hematopathology. She received a B.S. *summa cum laude* in Chemical Engineering from Rice University, a M.Phil. from University College London as a British Marshall Scholar and M.D. and Ph.D. degrees from the University of Michigan. She did postdoctoral work at MIT before completing her AP residency and a Hematopathology fellowship at Johns Hopkins Hospital.

Dr. Crane has authored more than 30 journal articles and has 2 related patents. She is Section Editor for Hematopathology at Arch Pathol Lab Med and PathologyOutlines.com, a reviewer for multiple pathology journals and is on the Education Committee for the Society of Hematopathology. Follow her on twitter @evemariecrane.