



THE LATEST NEWS IN GU / ADRENAL

By Debra L. Zynger, M.S., M.D.

As of January 1, 2018, the 8th edition of the American Joint Committee on Cancer (AJCC) Cancer Staging Manual and corresponding College of American Pathologists (CAP) cancer protocols should be used.

There are many minor modifications to Genitourinary and Adrenal staging and synoptic reporting, with the changes and relevance to your practice described in this newsletter. The most critical updates are indicated in orange. The impact to clinical management based on your synoptic report and the pTNM that you provide are listed below.

Testicle and penis have undergone substantial changes to the pT categorization. **Pheo-chromocytoma/paraganglioma** have a newly created pTNM staging system.

PROSTATE

- **pT2 is no longer subcategorized.** Because of this, you no longer need to note or designate the laterality of the tumor.
- Grade group has been added to the CAP cancer protocol as a required element. This does not replace Gleason score. Grade groups are defined as: 1=Gleason 5-6, 2=Gleason 3+4=7; 3=Gleason 4+3=7, 4=Gleason 8; 5=Gleason 9-10.
- **Impact to clinical management:** If the tumor is pT3a or higher, has positive surgical margins or is pN1,

adjuvant androgen deprivation or external beam radiation therapy can be considered.

TESTIS

- **There are major changes to the pT categorization for testicular tumors.**
- Germ cell tumor subtype now impacts pT categorization in the orchiectomy. Tumor subtype continues to be critical in the subsequent retroperitoneal lymph node dissection and other metastatic locations because if there is non-teratomatous tumor in these specimens, additional chemotherapy is given.
- **Pure seminoma is subcategorized based on a size threshold of 3 cm—**pT1a if < 3 cm and pT1b if ≥ 3 cm, therefore an accurate gross measurement is relevant.
- **Epididymal invasion is now pT2.** Epididymal invasion is very uncommon.
- **Hilar soft tissue invasion is now pT2.** Hilar soft tissue invasion is uncommon (Figure 1).

- Rete testis stromal invasion is associated with more aggressive tumors and is a required reporting element but does not impact pT category.
- Discontinuous invasion of the spermatic cord is now pM1b. This finding is extremely rare.
- Tips regarding lymphovascular invasion: Seminoma is friable and thus if grossed fresh often has tumor artifactually displaced into lymphovascular spaces and throughout the tissue. Tumors with lymphovascular invasion are typically seminomas larger than 4 cm or mixed germ cell tumors with greater than 25% embryonal

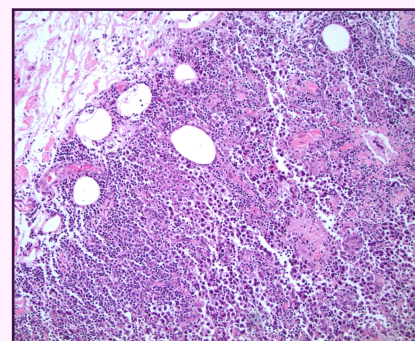


Figure 1: Seminoma involving hilar fat. Hilar fat invasion is now categorized as pT2.

carcinoma. Lymphovascular invasion in the spermatic cord is pT2 (not pT3). If possible, bisect the testicle and fix overnight, to greatly reduce artifactual lymphovascular invasion.

- Be aware that node pN category is based on the size of the involved lymph node, unlike many other organs which utilize the size of the metastatic deposit in the node.
- Regarding testicular sex cord stromal tumors, you can use the CAP testis protocol but **the AJCC stage is only applicable to malignant testicular sex cord stromal tumors.**
- **Impact to clinical management of seminoma:** If node negative, usually surveillance is recommended with adjuvant single agent carboplatin or radiation considered. If node positive, adjuvant chemotherapy or radiation is given.
- **Impact to clinical management of mixed germ cell tumor:** If pT2, the patient undergoes a retroperitoneal lymph node dissection or receives chemotherapy. If pN2-3, chemotherapy is utilized.

KIDNEY

- Per the CAP cancer protocol, you must now note coagulative necrosis and rhabdoid morphology, in addition to sarcomatoid differentiation. None of these variables currently impact standard clinical management.
- **Microscopic identification of tumor in the renal vein or its branches is now sufficient for the pT3a category;** you no longer need to see the tumor thrombus grossly. **Muscle no longer needs to be visualized** for a vessel to be classified as a renal vein segmental branch.
- **Pelvicaleiceal invasion is now a part of pT3a.** It is very rare to have pelvicaleiceal invasion without renal sinus fat invasion (which would already make the tumor pT3a).
- **Impact to clinical management:** If a renal cell carcinoma is clear cell histologic type and pT2-4 or pN1, the patient has the option of adjuvant sunitinib or placement in a clinical trial, although the mainstay of treatment is surveillance.

PENIS

- **There are major changes to the pT categorization of penile squamous cell carcinoma.**
- **Tumor with perineural invasion is now categorized as pT1b.**
- **Invasion of the corpus cavernosum is now pT3 rather than pT2.**
- Invasion of the urethra, which had been pT3, is no longer included in pT categorization.
- **Impact to clinical management:** For patients that are pT1b-4, an inguinal lymph node dissection is recommended. If inguinal lymph nodes yield pN2-3, a pelvic lymph node dissection, chemotherapy and radiation are considered.

ADRENAL CORTEX

- Per the CAP cancer protocol, you must note the histologic types of adrenal cortical carcinoma

(oncocytic, myxoid and sarcomatoid) (Figure 2).

- Per the CAP cancer protocol, you must **grade the tumor as high or low grade based on number of mitotic figures with a threshold of 20 mitoses per 50 high powered fields**—high grade if > 20 mitoses and low grade if ≤ 20 mitoses.

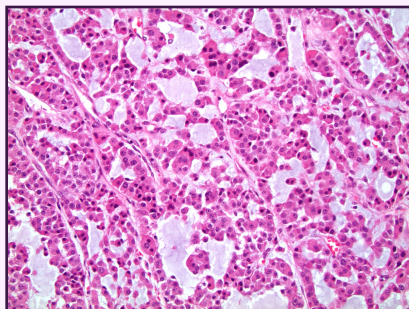


Figure 2: Adrenal cortical carcinoma, myxoid type. Per the CAP cancer protocol, there are 3 subtypes to report: oncocytic, myxoid and sarcomatoid.

- **Impact to clinical management:** If the tumor is high grade, has positive margins, is a large size or has a ruptured capsule, adjuvant external beam radiation therapy or mitotane are considerations.

PHEO-CHROMOCYTOMA/ PARANGLIOMA

- **There is a new AJCC pTNM staging system** but currently no CAP cancer protocol.
- **Size is used in pT categorization based on a threshold of 5 cm**—pT1 if < 5 cm and pT2 if ≥ 5 cm.
- **Invasion into surrounding tissue is pT3.**
- **Impact to clinical management:** None. Patients undergo surveillance.

SCROTUM

- **The AJCC pTNM staging system and CAP cancer protocol for skin squamous cell carcinoma have been discontinued.**

BLADDER

- No substantive changes.

- **Impact to clinical management:** If the tumor is pT3-4 or pN1-3 and no neoadjuvant chemotherapy was given, adjuvant chemotherapy may be utilized.

RENAL PELVIS/ URETER

- No substantive changes.
- **Impact to clinical management:** If pT2-4 or pN1-2, adjuvant chemotherapy is considered.

URETHRA

- No substantive changes.
- **Impact to clinical management:** If pT3-4, pN1-2 or a positive margin, adjuvant chemotherapy, chemoradiation or additional surgery are considered.

MEET THE AUTHOR



Dr. Debra Zynger, M.S., M.D., is an Associate Professor and the Director of the Division of Urologic Pathology at The Ohio State

University Medical Center.

She earned an M.S. in Genetics from Stanford University and an M.D. from Indiana University. Dr. Zynger completed her residency training in Anatomic and Clinical Pathology at Northwestern University and her Genitourinary Pathology Fellowship at the University of Pittsburgh.

Dr. Zynger has authored two Genitourinary Pathology textbooks, published more than 80 journal articles, has served as a peer reviewer for 35 journals and is on multiple editorial boards. Dr. Zynger presents numerous talks at national conferences and is the College of American Pathologists delegate chair for Ohio.