PathologyOutlines.com

WHAT'S NEW IN PATHOLOGY?

Issue 10 || March 2019

Revised 17May19

THE LATEST NEWS IN BREAST PATHOLOGY

By Emily S. Reisenbichler, M.D.

What's New in Breast Pathology includes changes from the AJCC 8th Edition, HER2 guidelines from ASCO / CAP, PDL1 staining, recommendations for handling neoadjuvant therapy specimens and DCIS active surveillance clinical trials.

Breast Cancer Staging, AJCC, 8th Edition (2017)

- **Lobular carcinoma in situ** (LCIS) **has been removed from pTis** because it is considered a benign risk lesion (**Fig. 1**).

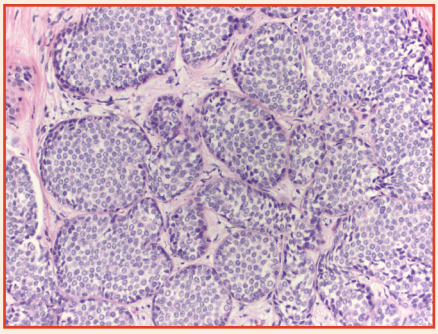

***Fig. 1**: Classic type LCIS, now considered a benign risk lesion and no longer included in the AJCC Cancer Staging System as pTis.*

- Histologic grade and biomarker status (including ER, PR and HER2) are incorporated into clinical prognostic staging.

Sponsored by an unrestricted grant from Yale University School of Medicine

- The multigene test, Oncotype DX®, is included in the prognostic stage as the only test showing level I evidence of prognostic and therapy predictive information. Tumors that are pT1 or pT2, hormone receptor positive, HER2 negative and lymph node negative with Recurrence Scores < 11 are downstaged to the same prognostic stage as T1a - T1b N0 M0 cancers (Stage IA).
- The TAILORx clinical trial showed that patients with Recurrence Scores of 11 - 25 can be spared chemotherapy but subset analysis showed a chemotherapy benefit for early breast cancer patients ≤ 50 years old with scores of 16 - 25 (N Engl J Med 2018;379.111).

2018 Update to the ASCO / CAP HER2 Guidelines

- A focused update addressed key HER2 scenarios (Arch Pathol Lab Med 2018;142.1364).
- A 2+, equivocal HER2 result by IHC is now defined as weak to moderate complete membrane staining in > 10% of invasive tumor cells (**Figs. 2 and 3**).

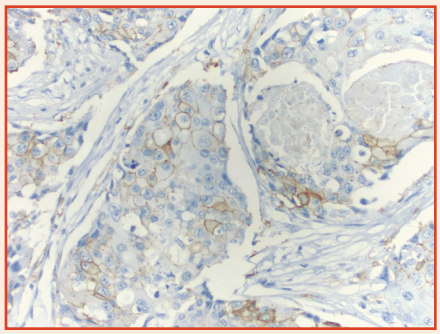

***Fig. 2**: HER2 immunohistochemical stain showing weak, complete membranous staining of > 10% of invasive tumor cells; interpreted as equivocal (2+).*

- **A HER2 negative result on core biopsy does not necessitate repeat testing on the excision in all cases.**
- HER2 may be repeated on excision if the tumor is grade 3, the amount of invasion in the core biopsy is small or there is a high grade region in the excision that is morphologically distinct from that in the core.
- HER2 should not be repeated on excision if the initial core biopsy is HER2 negative and is either hormone receptor positive or tubular, mucinous or adenoid cystic carcinoma.
- The FISH testing algorithm was updated. IHC is needed for equivocal FISH results (see below), and if still equivocal (2+), additional cells for FISH are counted. If the ratio and average HER2 remain the same, the final result is interpreted as HER2 negative with a comment (Arch Pathol Lab Med 2018;142.1364. figs. 4, 5 and 6).

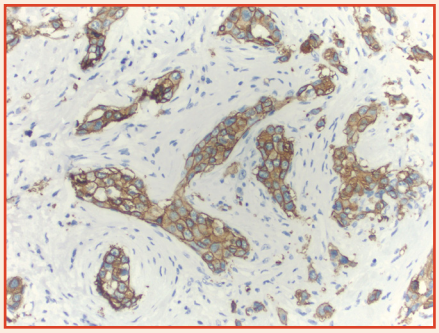

***Fig. 3**: HER2 immunohistochemical stain showing strong, intense complete membranous staining of > 10% invasive tumor cells (nearly all cells in this particular case); interpreted as positive (3+).*

- Formerly equivocal FISH results.
(a) Ratio ≥ 2.0 and HER2 copy number < 4.0 signals per cell.
(b) Ratio < 2.0, average HER2 copy number ≥ 6.0 per cell.
(c) Ratio < 2.0, average HER2 copy number > 4.0 and < 6.0.

PD-L1 Testing in Breast Cancer

- The IMpassion130 trial has demonstrated prolonged progression free survival in patients with **metastatic triple negative breast cancer** (ER / PR / HER2 negative)

and PD-L1 positive immune cells, treated with the PD-L1 inhibitor, **atezolizumab** (N Engl J Med 2018;379.2108).

- **PD-L1 positivity in this trial was defined as PD-L1 expression (using Ventana SP142 antibody) in > 1% tumor infiltrating immune cells.**
- In lung carcinoma, SP142 antibody has a low sensitivity for tumor cells and tumor infiltrating immune cells when compared with other PD-L1 antibody clones (JAMA Oncol 2017;3.1051).
- In March 2019, the FDA approved the SP142 assay as a companion diagnostic to identify patients eligible for treatment with atezolizumab plus chemotherapy.
- How does this affect pathologists? PD-1 and PD-L1 inhibitors are new treatments for non small cell lung carcinoma, melanoma, bladder and breast carcinoma. Medical oncologists request PD-L1 testing to predict response to checkpoint inhibitors in breast cancer. Pathologists should know which assay is used and how to score / evaluate this immunohistochemical stain. Interpretation cutoffs currently lack standardization and vary in different tumor types.

Recommendation of Standardized Evaluation And Reporting Response to Neoadjuvant Therapy in Breast Cancer Surgical Specimens

- Neoadjuvant chemotherapy is routinely used for triple negative and HER2 positive tumors (**Fig. 4**).

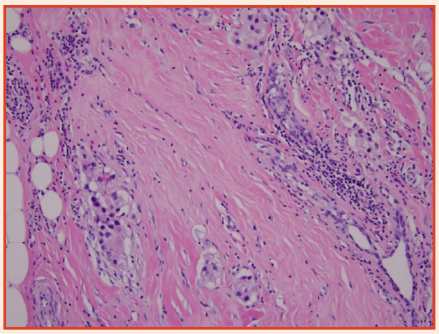

***Fig. 4**: Post treatment residual tumor and giant cells.*

- Multiple systems exist for assessing post neoadjuvant therapy specimens to quantify the response to therapy (i.e. Miller-Payne, Sataloff, Chevallier methods). New recommendations were recently made (Mod Pathol 2015;28.1185)**.**
- An image (drawing, photo or radiograph) of the sliced specimen should be maintained with a map of submitted tissue sections.
  - In small specimens with no gross tumor, submit the entire specimen.
  - Attempt to quantify residual tumor in large specimens, sample any grossly visible tumor or location of biopsy clips; in the absence of gross tumor, sample the largest cross sectional area of the pretreatment tumor area (submit 5 blocks per 1 - 2 cm pretreatment size, up to 25 total blocks).
- Quantify and report residual tumor using the MD Anderson calculator for Residual Cancer Burden (RCB), see https://www.pathologyoutlines.com/site/MDA.html.
- Complete pathologic response (pCR) means no residual invasive tumor, lymphatic or lymph node involvement.
- Residual DCIS only is considered pCR (AJCC 8th agrees).
- There is no consensus regarding the need for reassessment of hormone receptor and HER2 status in residual cancer postneoadjuvant therapy (Hum Pathol 2017;62.215).

DCIS Active Surveillance Clinical Trials

- Overdiagnosis and overtreatment of ductal carcinoma in situ (DCIS) is an ongoing debate and recent clinical trials are exploring active surveillance as an alternative to surgical management.
- How does this affect pathologists? Since DCIS **grade** and the presence of **comedonecrosis** are specific inclusion / exclusion criteria for these trials, it is **important to report these features for core biopsies**.
- Management of Low Risk DCIS (LORD). NCT02492607. Recruitment July 2015. Surgery +/- radiation with choice for endocrine therapy versus annual mammogram for 10 years.
- Low Risk DCIS Trial (LORIS). ISRCTN.27544579. Recruitment July 2014. Surgery +/- radiation versus annual mammogram for 10 year period.
- Comparison of Operative to Monitoring and Endocrine Therapy (COMET). NCT02926911. Recruitment October 2016. Surgery +/- radiation with choice for endocrine therapy versus mammograms every 6 months with choice for endocrine therapy.
- Low and Intermediate Risk Ductal Carcinoma in situ Study (LARRIKIN). Recruitment pending. Surgery +/- radiation versus mammographic surveillance.

Subscribe to this free newsletter by visiting www.pathologyoutlines.com/subscribe.html

Meet the Author

Emily Reisenbichler is an Assistant Professor of Pathology and director of the breast pathology fellowship at Yale University in New Haven, CT. She earned her M.D. at the University of Texas Medical Branch in Galveston, TX, followed by residency in Anatomic and Clinical Pathology at the University of Alabama-Birmingham, AL. She completed breast and surgical pathology fellowships at Brigham and Women's Hospital, Boston, MA.

Dr. Reisenbichler is the breast pathology editor for PathologyOutlines.com. She is on the editorial board for the American Journal of Clinical Pathology and serves as a peer reviewer for several journals.